

Endovascular treatment experiences on complex aorto-iliac aneurysms

Endovascular approaches for aorto-iliac aneurysms

Tanil Özer, Mustafa Akbulut, Mustafa Mert Ozgur, Mehmet Aksut, Mesut Şişmanoğlu, Kaan Kırılı
Department of Cardiovascular Surgery, Health Sciences University,
Kartal Kosuyolu High Specialization Training and Research Hospital, Istanbul, Turkey

Abstract

Aim: Nowadays, endovascular approach in abdominal aortic aneurysms has almost replaced open surgery. The strategy is common and relatively easy when it can be terminated in both common iliac arteries. Conversely, in cases where it has to be extended to the external iliac artery, the decision for additional intervention in the internal iliac artery is controversial. This study aimed to share our experiences on endovascular approaches to aorto-iliac aneurysms.

Material and Methods: This study included 28 patients who underwent EVAR, which was extended to the EIA. Anatomical shape of IIA, interventional success, presence of leakage, presence of complication related to IIA occlusion, and any time results were recorded and evaluated.

Results: The mean age was 68 + 9,3 (42–81) years with a higher male population (n: 24, 85,7%). Follow-up durations varied between 2 days and 26 months. In four patients, interventions were performed under emergency conditions. Iliac branched grafts were used for six patients. In three patients, IIA was occluded with occlusion devices. There was no transition to open surgical repair. Buttock claudication was seen in 8 patients (28,5%), and there was no new onset erectile dysfunction after occlusion of IIAs.

Discussion: AIAs may be treated with favorable results through endovascular approaches. Since decision- making will depend on the available devices in the clinic, treatment options can occasionally be changed. Therefore, learning different approaches might be helpful for practitioners.

Keywords

Abdominal aorta; Aortic aneurysm; Aorto-iliac aneurysm; Endovascular repair; Iliac artery

DOI: 10.4328/ACAM.20635 Received: 2021-04-05 Accepted: 2021-04-25 Published Online: 2021-04-30 Printed: 2021-05-01 Ann Clin Anal Med 2021;12(5):567-572
Corresponding Author: Tanil Özer, Cardiovascular Surgery Department, Health Sciences University, Kartal Kosuyolu High Specialization Training and Research Hospital, Denizler Cad. Cevizli Kavşağı No: 2 Kartal, 34865 Istanbul, Turkey.
E-mail: drtanilozer@gmail.com P: +90 2165001500 F: +902164596321
Corresponding Author ORCID ID: <https://orcid.org/0000-0002-2701-2058>

Introduction

Abdominal aortic aneurysms have a higher mortality risk with follow-up without any intervention when diameters exceed threshold [1]. In recent years, endovascular methods for aortic disorders have become more common than open surgeries [2]. Although open surgical repair (OSR) remains as a back-up technique for inappropriate anatomical situations, with increasing experiences, the rate of switching to open surgery has considerably decreased. Moreover, these experiences showed that some branches of major arteries also can be occluded without creating significant symptoms. Besides, some opinions were formed on how and when the occlusions can be performed. In some cases, particularly for the distal landing zone, extension to the external iliac artery (EIA) becomes inevitable. Thus, additional interventions may be necessitated to occlude or preserve the patency of the internal iliac artery (IIA), which has collateral branches to the pelvis and upper part of the lower extremities [3]. Consequently, the preferred intervention is related to the anatomical appropriateness of IIA, the content of the center, and the practice of performers. In this study, we would like to share our experiences on endovascular approaches to aorto-iliac aneurysms.

Material and Methods

From November 2015 to January 2020, 223 patients who underwent endovascular aortic repair (EVAR) for AAAs were retrospectively analyzed. Of these, 28 patients whose EVAR application needed extension to the EIA due to the absence of an appropriate distal landing zone at the common iliac artery (CIA) were included in the study. Those with aortic pathologies above iliac bifurcation were excluded. Approaches to the IIA while extending were evaluated. The anatomical shape of IIA, interventional success, the presence of leakage, the presence of complication related to IIA occlusion, and any time results were assessed. Two classifications which were mentioned in European Society for Vascular Surgery (ESVS) 2019 clinical practice guidelines on the management of abdominal aorto-iliac artery aneurysms were just used to simplify the visualization of the readers: Reber's classification was used for the definition of the anatomical structure of CIA, while Fahrni's classification was used in considering the options for intervention to IIA (4,5). The success of the intervention was mentioned for the usage of any iliac branched graft (IBG) and defined as the ability to completely place the IBG. Any type of endoleak was included if it was present. Complications related to IIA occlusion were identified as follows: new onset erectile dysfunction, buttock claudication, and ischemia of the colon, which was proved with radiologic imaging.

Informed consent forms to share their data, excluding personal identification information, were obtained from all patients who participated in this study. The study protocol was approved by the Institutional Clinical Trial Review Board of Health Science University Kartal Kosuyolu High Specialization Training and Research Hospital (2020.4/27-332). The study was conducted in accordance with the principles of the Declaration of Helsinki.

Statistical Analyses:

Statistical analyses were performed using the SPSS version 23 software (IBM Inc, Armonk, NY). The Kolmogorov–Smirnov and

Shapiro–Wilk tests were used to assess the normality of the variables. Continuous variables were expressed as mean \pm 1 standard deviation, and categorical variables as percentages.

Results

The mean age of the patients was 68 + 9,3 (min: 42 - max: 81) with the male population generally higher than that of females (n:24, 85,7%; n:4, 14,3%). The most frequent features of patients were smoking (n:14, 50%) and hypertension (n:10, 35,7%) and coronary artery disease (CAD) (n:9, 32,1%) (Table 1). Three of the patients were treated for primarily iliac artery aneurysm (IAA) as the AAAs have not reached the interventional threshold yet. The IAA was mostly seen bilateral (n:018 (64,2%), and the mean CIA diameter was approximately the same for both right and left sides (31,9+15,2 mm; 29,9+17,5 mm) (Table 2). While the iliac arteries were assessed separately, the anatomical structures of the CIA were mostly similar with type 1 according to Reber's classification (n: 24, 42,8%). The structural assessment of IIAs for any intervention was mostly appropriate with type 1b of Fahrni's classification (n: 36, 62,2%) (Table 2). In four patients, interventions were performed under emergency conditions. IBGs were used in six patients [1 x Gore Excluder IBE (W. L. Gore and Associates, Flagstaff, Ariz), 5 x E-iliac (JOTEC, Hechingen, Germany)]. While introduction of IBG to one patient was not successful due to anatomical difficulties, bilateral introduction was performed successfully to another patient (Figure 1). Bilateral IIA occlusions were performed in 6 patients, and the most used method for occlusion was the extension of stent graft to EIA without any occlusion devices. The vascular plug was used in only three patients, while the coil was not used in any patient. Switching to OSR was not needed, and concomitant interventions were required for three patients. These additional interventions were embolectomy (n:2) and stent implantation to EIA due to kinking of the extended stent graft caused by massive angling of EIA. Only four patients' interventions were completed with the presence of endoleak, which could be seen in an angiographic view. Three patients had type 2 endoleak, and one patient whose IBG implication was considered unsuccessful had type 3 endoleak (Table3).

All patients were discharged from the hospital. The mean length of ICU stay was 1,17 + 0,49 days (min: 1 - max: 3), and the mean length of hospital stay 3,69 + 1,55 days (min: 2 - max: 7). During follow-up, 3 patients had an endoleak: one type 1b (Figure 2), one type 2, and one type 3. The new onset erectile dysfunction occurred in only one patient. This patient was the one whose bilateral IIAs were protected with IBGs. Buttock claudication was seen in 8 patients, and only one of them lasted more than 2 months.

Six patients underwent re-intervention at any time during the follow-up. Procedures performed were as follows: embolectomy and stent implication to extended stent graft at postoperative day 2 (n:2), extension with a stent graft after 14 months due to enlargement of CIA (n:1), stent implication to extended stent graft due to kinking at the stent graft (n:1), cross femoral bypass (n:1), and coil embolization to the collateral branch, which caused type 2 endoleak (n:1) (Figure 3).

The duration from performing the case to last CTA control ranged from 2 days to 26 months.

Table 1. Demographic Data

	n (28) (100%)
Age (year)	68 + 9,3 (min: 42 - max: 81)
BMI	26,8 + 2,4 (min: 22,7 - max:31,3)
Gender	
Male	24 (85,7%)
Female	4 (14,3%)
CAD	9 (32,1%)
PAD	5 (17,8%)
COPD	5 (17,8%)
CRD	3 (10,7%)
DM	2 (7,1%)
Hypertension	10 (35,7%)
Smoking	14(50%)
Previous Cardiac Surgery	6 (21,4%)
Previous Abdominal Opening	1 (3,5%)

BMI: Body mass index, min: Minimum, max: Maximum, CAD: Coronary Artery Disease, PAD: Peripheral Artery Disease, COPD: Chronic Obstructive, CRD: Chronic Renal Disease, DM: Diabetes Mellitus

Table 2. Anatomic Features of Aneurysm

Diameter of Abdominal Aorta (mm)	68,9 + 21,5 (min: 26 - max: 115)
Diameter of Common Iliac Artery (mm)	
Right	31,9 + 15,2 (min: 11 - max: 57)
Left	29,9 + 17,5 (min: 13 - max: 80)
Side of Aneurysmatic Iliac Artery	n: 28 (100%)
Right	6 (21,4%)
Left	4 (14,2%)
Bi-iliac	18 (64,2%)
Reber's Classification	n: 56 (100%)
Type 1	24 (42,8%)
Type 2	None
Type 3	8 (%)
Type 4	3 (5,3%)
unclassified	21(37,5%)
Fahmi's Classification	n: 56 (100%)
Type 1a	4 (7,1%)
Type 1b	36 (62,2%)
Type 2a	2 (3,5%)
Type 2b	None
Type 2c	3 (5,3%)
unclassified	11(19,6%)

Table 3. Interventions to Iliac Arteries

	N:28 (100%)
Urgent	4 (14,2%)
Usage of Iliac Branched Graft	
Right	2 (7,1%)
Left	2 (7,1%)
Bi-iliac	1 (3,5%)
Unsuccessful	1 (3,5%)
Occlusion of IIA	
Right	8 (28,5%)
Left	9 (32,1%)
Bi-iliac	6 (21,4%)
With extension of stent-graft	20 (71,4%)
With plug	3 (10,7%)
With coil	None
Endoleak	
Type1b	None
Type 2	3 (10,7%)
Type 3	1 (3,5%)
Switching to OSR	None
Additional intervention	3 (10,7%)

IIA: Internal Iliac Artery, OSR: Open Surgical Repair

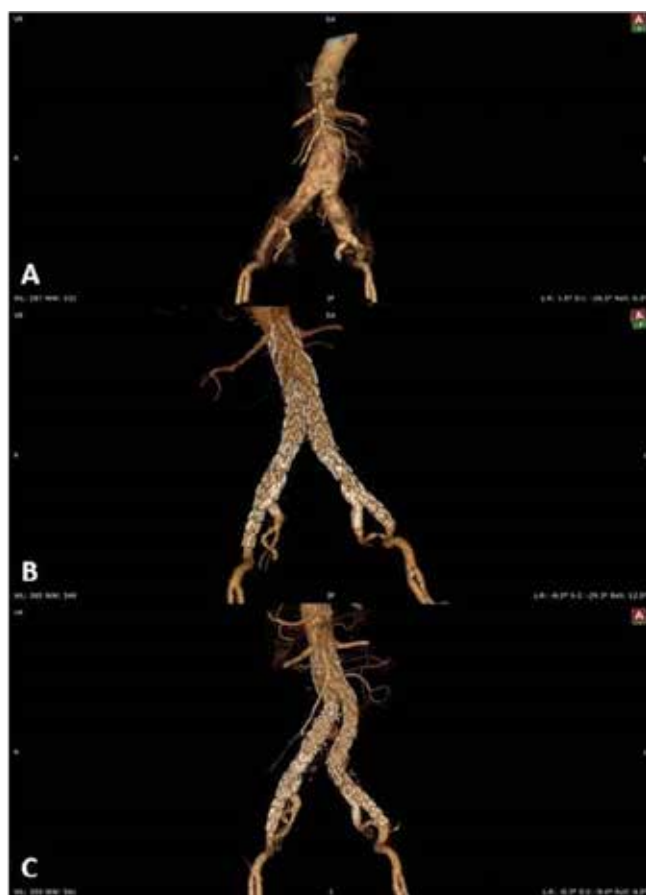

Figure 1. 3D imaging of the patient with bilateral IBG

- A: Pre-intervention image
- B: Post-intervention image (after 1 month)
- C: Post-intervention image (after 20 month)

Discussion

With the increase in the technological infrastructure and experiences of physicians, the use of endovascular methods in AAAs has become more frequent than OSR [2].

According to the ESVS guideline, which was published last year, EVAR had a lower mortality rate compared with both the OSR and no-intervention groups among patients with reasonable

life expectancy and suitable anatomy [6].

Performing EVAR applications may be relatively easier if the patient's anatomy is in accordance with the manufacturer's instruction for use (IFU). This appropriateness means that the presence of proper sealing zones for both the distal and proximal parts without significant angulations. However, it is known that approximately 10% of AAAs are present with IAAs and are called aorto-iliac aneurysms (AIA) [7]. In our clinic, we met a little more frequently with 12,5% (28/223).

Aorto-iliac aneurysms mainly have to overcome two issues when placing the distal legs of the stent grafts: first is about the

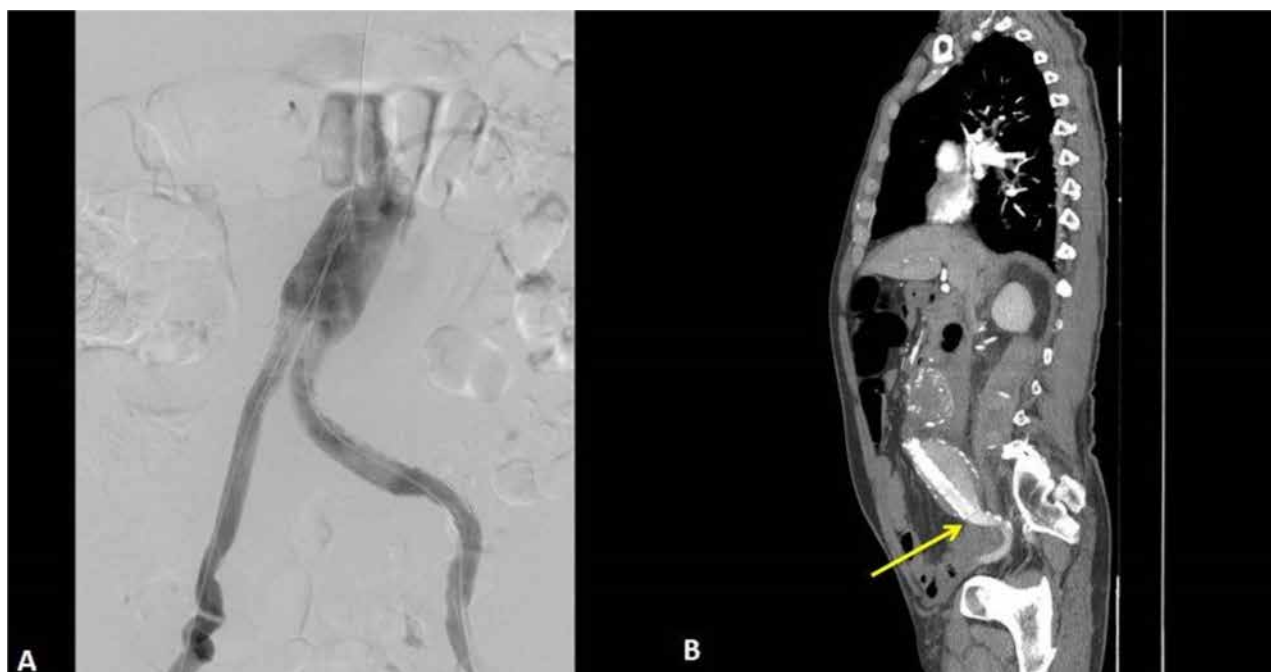

Figure 2. The patient with bilateral IBG and persistent Type 2 endoleak which was embolised with coil
 A: Angiographic view showed no endoleak
 B: Control CTA two days later with Type 1b endoleak
 Yellow arrow showed stent-graft migrated from distal landing zone

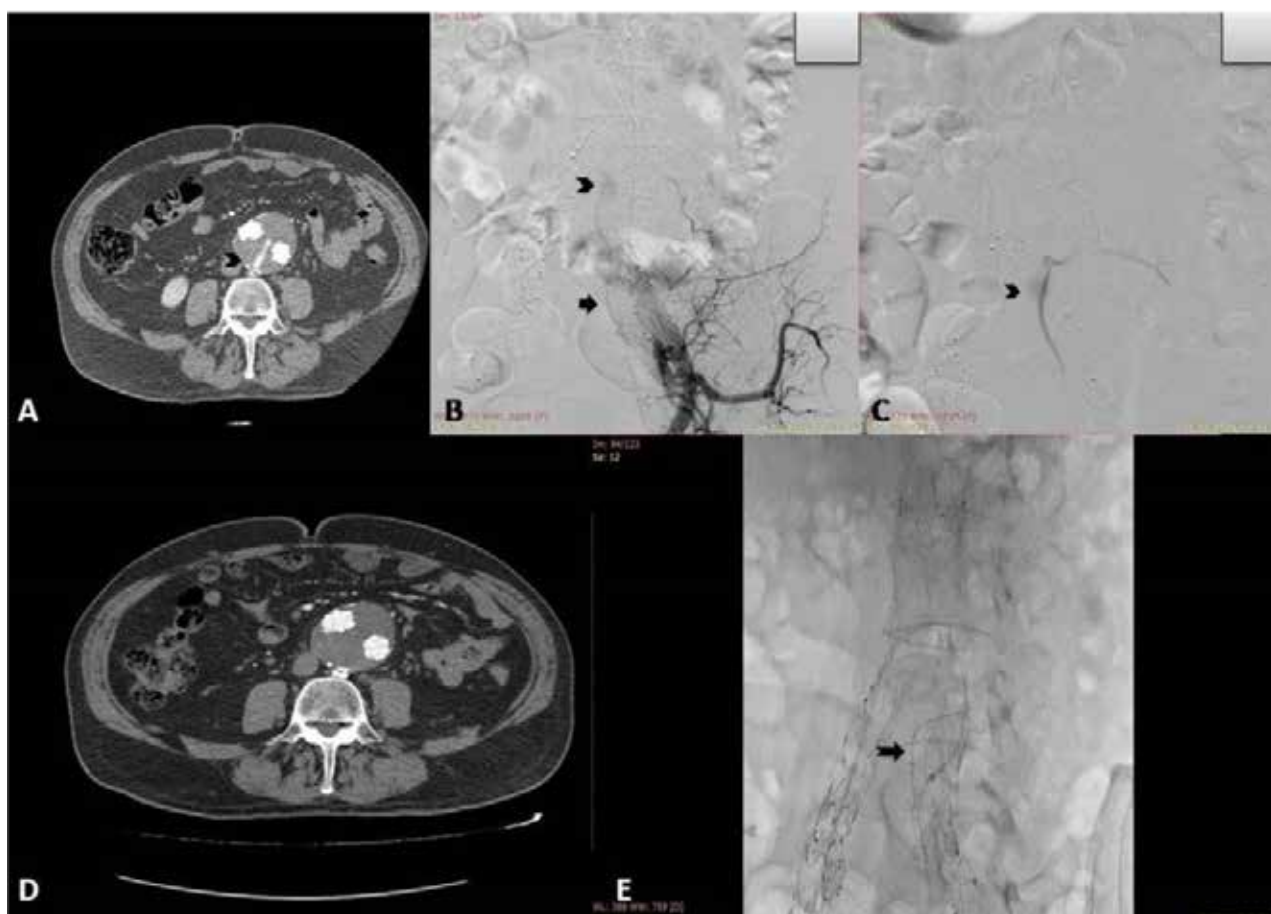


Figure 3. Patient with migrated distal extension from sealing zone causing Type 1b endoleak
 A: 2D image before embolization
 Bold black triangle bracket showed contrast agent originate from collateral branch
 B, C: Angiographic view before embolization
 Bold black triangle bracket showed contrast agent originate from collateral branch
 Bold black arrow showed collateral branch originated from IIA
 D: 2D image after embolization (contrast agent disappeared after embolization)
 E: View with scope of coil and endovascular devices
 Notched arrow showed coil inside the collateral branch originate from IIA

landing zones, and the second one is about IIA. Despite these debates, endovascular repairs, whose advantages have been commonly mentioned in publications, became more preferable than OSR due to the higher risk for pelvic structure injury during challenging exploration of IIAs [8,9].

Several techniques have been described to ensure IIA openness during EVAR [10]. The bell-bottom technique (also called flared limb technique) is preferred when the maximum CIA diameter does not exceed 26 mm. Although it is an easy technique compared to others, it is applied assuming that the main iliac artery is healthy. However, the risk of the requirement to re-intervention or rupture due to continuing enlargement of the CIA limits the preference for this technique. This technique may be preferable to reduce the operation time and radiation exposure, especially for elderly patients [11]. In this study, the bell-bottom technique has been used for two patients. Both patients had bilateral IIAs, while only one side was appropriate for the bell-bottom technique (Reber's type 1, Fahrni's 1b). We preferred this technique to both patients, not only to preserve openness of the IIA, but also to avoid possible kinking due to a very narrow angulation. One of these patients underwent iliac extension with a stent graft as a re-intervention due to enlargement of the CIA after 14 months, while the comparatively young one (58 years) had no re-intervention. Consequently, in our opinion, the bell-bottom technique may be considered when the existence of massive tortuosity or angulations restricts extension to EIAs. Other methods, which require additional tools and accesses, are thought that all segments of AIA can be excluded while preserving the IIA's patency [12-14]. Among these techniques, IBG has been gaining popularity in recent years owing to be the most appropriate with natural anatomy and can be applied via the same femoral accesses [15]. On the other hand, their restriction includes the requirement to comply with the IFU of manufacturers such as all endovascular devices. A study by Muzepper et al. evaluated the anatomical suitability of two different brands of IBGs with Chinese [16]. According to their study, only 20.6% of Chinese patients were eligible for IBGs. It is obvious that this study had significant limitations due to not including all brands in the market. However, in many clinics, the provision of treatment strategies can be limited, since product supply is provided through periodic contracts. Thus, similar limitations might implicate practitioners while decision-making. IBG was performed to 6 patients, and the E-iliac stent grafts were used 5 times. While the application techniques of both devices were very similar, diameter ranges were wider at Gore Excluder IBE, which turned out to be an unsuccessful case. This patient has been surviving for more than 2 years with a type 3 endoleak, which was tried to be resolved with extension with another stent graft as a re-intervention one month after the first case. We also experienced the application of IBGs bilaterally to a patient. This patient was a very active 64-year-old male, and we considered to try to preserve both sides of the IIA to minimize the erectile dysfunction (ED) and buttock claudication (BC) risks, which were the most frequently seen uncomfortable complications after IIA occlusion [17]. Although bilateral placement of IBGs has been successfully performed and patency of bilateral IIAs was secured, interestingly the patient suffered with new-onset ED. ED, which is associated

with many causes, may develop after EVAR, which is not related to IIA occlusion.

Endovascular treatment strategies of AIAs originally involved occlusion of IIA and extension to EIA with a stent graft. The occlusion of IIA has collateral branches that supply the pelvic viscera, and also some muscle groups in the buttocks and thighs may cause disruption of the circulation. Thankfully, although these possible ischemic complications seemed serious, these are seen very rarely owing to pelvic collateral circulation [18,19]. In our experience, eight patients encountered BC, while only one of them complained that it lasted for more than two months. Serious ischemic complications related to occlusion of the IIA were not observed.

The occlusion of the IIAs was another issue during extension to EIAs for endovascular treatment of AIAs. These can be achieved with plug, coil, or coverage alone. Fahrni et al. suggested a classification with a study in 2003 about occlusion options for IIA when the extension to EIA was needed [4]. In this study, although we did not meet treatment options, we used this classification to give an idea in terms of anatomical suitability. Additionally, we have never used any coil to occlude any segment of IIA during EVAR procedures. Tefera et al. in their publication in 2004 showed that the coverage alone without a coil effectively created embolization with even lesser complication rates [20]. The vascular plug was used in only three patients whose IIA orifice seemed wide. On the other hand, with increasing experience, performing occlusion with coverage alone is encouraged for most situations. Additionally, only 2 patients had a type 2 endoleak related to IIA, with spontaneous resolutions, which occurred in 2 months without causing sac expansion.

Since the resolution of type 2 endoleaks mostly occurs spontaneously, following minimal type 2 endoleaks with a conservative approach is recommended until the expansion of sac diameter reaches 1cm threshold [21]. While type 2 endoleaks in 2 patients spontaneously thrombosed, the other type 2 endoleak lasted 20 months in a patient whose bilateral IIAs were preserved with IBGs. This patient also was under warfarin treatment due to mechanical aortic valve replacement history. Consequently, this endoleak, which originated from the collateral artery between the IIA and lumbar artery, was followed through so that the enlargement did not reach 1cm, until a deterioration at graft configuration occurred. This endoleak was occluded with a coil through the left IIA percutaneously. Hereby, it might be considered that the preservation of IIA enabled us to perform this intervention through trans-arterial approach. Accordingly, this situation may be counted as another advantage of preserving IIA during EVAR.

Although experts have recommended that type 1 and 3 endoleaks should be resolved promptly [6], 2 patients in this study had endoleaks type 1b and type 3 as far as we know. The patient who was already mentioned above with an unsuccessful implantation of IBG had a type 3 endoleak. This patient was under close follow-up, and the endoleak did not cause expansion at AAA or IAA.

Another patient with type 1b endoleak underwent emergency surgery. Although the last control with digital subtraction angiography (DSA) showed successful deployment of the stent

graft with extensions to both EIAs, migration proximally from the distal sealing zone, causing type 1b endoleak, was observed with CTA two days later. Thus, although additional contrast usage was needed at a very close time intervals, CTA control might be considered promptly after the intervention, if it cannot be determined accurately prior to the intervention due to emergency conditions. On the other hand, since this patient did not give consent, no further attempts could be made to resolve the problem. To the best of our knowledge, this patient still lives with a current endoleak outside our follow-up.

Additional interventions, which include switching to OSR, may be needed during primary case or follow-up periods. Among patients whose vascular structures were affected by several comorbidities like age, atherosclerosis, etc., the risk for additional or re-interventions may increase with a strong relationship with anatomic disruptions [22]. In this study, switching to OSR was not necessary, while two patients underwent additional femoral embolectomy. Additionally, except for the re-interventions mentioned above, our re-intervention experiences included iliac occlusions due to stenosis and kinking of iliac extensions. Particularly, kinking might be predicted using 3D-converted images when planning treatment strategies. Otherwise, the stiff wires may mislead performers to flatten its tortuosity, which assumed that favorable results were obtained during DSA imaging. In addition, adjunctive stenting to narrow angled part as prophylaxis might be a good idea particularly for high-risk patients [23].

In conclusion, AIAs could be treated with favorable results via endovascular approaches.

To preserve the patency of IIA with any technique may be the first target for the patients with suitable anatomy. However, occlusion of IIAs, even with just extended stent graft, does not have significantly worse outcomes than preserving clinical results. Additionally, evaluation with multi-planar reconstruction and 3D imaging before interventions should be considered to predict possible issues and develop strategies to overcome such issues. Since decision-making will depend on the available devices in the clinic, treatment options can occasionally be changed. Therefore, learning different approaches might be helpful for practitioners.

Scientific Responsibility Statement

The authors declare that they are responsible for the article's scientific content including study design, data collection, analysis and interpretation, writing, some of the main line, or all of the preparation and scientific review of the contents and approval of the final version of the article.

Animal and human rights statement

All procedures performed in this study were in accordance with the ethical standards of the institutional and/or national research committee and with the 1964 Helsinki declaration and its later amendments or comparable ethical standards. No animal or human studies were carried out by the authors for this article.

Funding: None

Conflict of interest

None of the authors received any type of financial support that could be considered potential conflict of interest regarding the manuscript or its submission.

References

- Parkinson F, Ferguson S, Lewis P, Williams IM, Twine CP, South East Wales Vascular Network. Rupture rates of untreated large abdominal aortic aneurysms in patients unfit for elective repair. *J Vasc Surg.* 2015;61(6):1606-12.
- Chaikof E, Dalman RL, Eskandari M, Jackson B, Lee A, Mansour M, et al. The Society for Vascular Surgery practice guidelines on the care of patients with an

- abdominal aortic aneurysm. *J Vasc Surg.* 2018;67(1):2-77.
- Sandhu RS, Pipinos II. Isolated iliac artery aneurysms. *Semin Vasc Surg.* 2005;18(4):209-15.
- Fahmi M, Lachat MM, Wildermuth S, Pfammatter T. Endovascular therapeutic options for isolated iliac aneurysms with a working classification. *Cardiovasc Intervent Radiol.* 2003;26(5):443-7.
- Reber PU, Brunner K, Hakki H, Stirnemann P, Kniemeyer HW. Häufigkeit, Klassifikation und Therapie der isolierten Beck- enarterienaneurysmen [Incidence, classification and therapy of isolated pelvic artery aneurysm]. *Chirurg.* 2001;72(4):419-24.
- Wanhainen A, Verzini F, Van Herzele I, Allaire E, Bown M, Cohnert T, et al. Editor's choice European Society for Vascular Surgery (ESVS) 2019 clinical practice guidelines on the management of abdominal aorto-iliac artery aneurysms. *Eur J Vasc Endovasc Surg.* 2019; 57(1):8-93.
- Richardson JW, Greenfield LJ. Natural history and management of iliac aneurysms. *J Vasc Surg.* 1988;8(2):165-71.
- Buck DB, Bensley RP, Darling J, Curran T, McCallum JC, Moll FL, et al. The effect of endovascular treatment on isolated iliac artery aneurysm treatment and mortality. *J Vasc Surg.* 2015;62(2):331-5.
- Chaer RA, Barbato JE, Lin SC, Zenati M, Kent KC, McKinsey JF. Isolated iliac artery aneurysms: a contemporary comparison of endovascular and open repair. *J Vasc Surg.* 2008;47(40):708-13.
- Bekdache K, Dietzek AM, Cha A, Neychev V. Endovascular hypogastric artery preservation during endovascular aneurysm repair: a review of current techniques and devices. *Ann Vasc Surg.* 2015; 29(2):367-76.
- Wang L, Liang S, Xu X, Chen B, Jiang J, Shi Z, et al. A Comparative Study of the Efficacy by using Different Stent Grafts in Bell- Bottom Technique for the Treatment of Abdominal Aortic Aneurysm Concomitant with Iliac Artery Aneurysm. *Ann Vasc Surg.* 2018; 52:41-8.
- Minion DJ, Xenos E, Sorial E, Saha S, Edean ED. The trifurcated endograft technique for hypogastric preservation during endovascular aneurysm repair. *J Vasc Surg.* 2008;47(3):658-61.
- Lobato AC. Sandwich technique for aortoiliac aneurysms extending to the internal iliac artery or isolated common/internal iliac artery aneurysms: a new endovascular approach to preserve pelvic circulation. *J Endovasc Ther.* 2011;18(1):106-11.
- Parlani G, Verzini F, De Rango P, Brambilla D, Coscarella C, Ferrer C, et al. Long-term results of iliac aneurysm repair with iliac branched endograft: a 5-year experience on 100 consecutive cases. *Eur J Vasc Endovasc Surg.* 2012;43(3):287-92.
- Mylonas SN, Rumenapf G, Schelzig H, Heckenkamp J, Youssef M, Schäfer JP, et al. A multicenter 12-month experience with a new iliac sidebranched device for revascularization of hypogastric arteries. *J Vasc Surg.* 2016;64(6):1652-9.
- Muzepper M, Zhou M. Anatomic Suitability of Iliac-branched Devices for Chinese Patients with Abdominal-iliac Aortic Aneurysm. *Ann Vasc Surg.* 2020; 67:178-84. DOI:10.1016/j.avsg.2020.03.010
- Rayt HS, Bown MJ, Lambert KV, Fishwick NG, McCarthy MJ, London NJ, et al. Buttock claudication and erectile dysfunction after internal iliac artery embolization in patients prior to endovascular aortic aneurysm repair. *Cardiovasc Intervent Radiol.* 2008;31(4):728-34.
- Lee CW, Kaufman JA, Fan CM, Geller SC, Brewster DC, Cambria RP, et al. Clinical outcome of internal iliac artery occlusions during endovascular treatment of aortoiliac aneurysmal diseases. *J Vasc Interv Radiol* 2000;11(5):567-71.
- Criado FJ, Wilson EP, Velazquez OC, Carpenter JP, Barker C, Wellons E, et al. Safety of coil embolization of the internal iliac artery in endovascular grafting of abdominal aortic aneurysms. *J Vasc Surg.* 2000;32(4):684-8.
- Tefera G, Turnipseed WD, Carr SC, Pulfer KA, Hoch JR, Acher CW. Is Coil Embolization of Hypogastric Artery Necessary during Endovascular Treatment of Aortoiliac Aneurysms? *Ann Vasc Surg.* 2004;18(2):143-6.
- Brown A, Saggi GK, Bown MJ, Sayers RD, Sidloff DA. Type II endoleaks: challenges and solutions. *Vasc Health Risk Manag.* 2016;12:53-63.
- Saba T, Duman E, Haberal C, Tünel A, Zülkü M. Requirement of intraoperative supportive procedures and complications in infrarenal abdominal aortic aneurysms due to iliac artery morphology. *Türk Gogus Kalp Damar.* 2017;25:381-7.
- Coelho A, Nogueira C, Lobo M, Gouveia R, Campos J, Augusto R, et al. Impact of post-EVAR graft limb kinking in EVAR limb occlusion: aetiology, early diagnosis, and management. *Eur J Endovasc Surg.* 2019; 58(5):681-9.

How to cite this article:

Tanil Özer, Mustafa Akbulut, Mustafa Mert Ozgur, Mehmet Aksut, Mesut Şişmanoğlu, Kaan Kırallı. Endovascular treatment experiences on complex aorto-iliac aneurysms. *Ann Clin Anal Med* 2021;12(5):567-572